

Three-Dimensional Printing for Planning Occlusion Procedure for a Double-Lobed Left Atrial Appendage

Yiting Fan, MM; Ka-Wai Kwok, PhD (Imp Lond); Yiquan Zhang;
Gary Shing-Him Cheung, MBBS; Anna Kin-Yin Chan, MBChB; Alex Pui-Wai Lee, MD

A 78-year-old woman with atrial fibrillation and contraindication to oral anticoagulation because of high bleeding risk was referred for catheter-based left atrial appendage (LAA) occlusion. Preprocedural transesophageal echocardiography (TEE) using the biplane mode showed an LAA with double-lobed anatomy with a dominant posterior lobe (p) and an accessory anterior lobe (a; Figure [A]). It was thought that successful LAA occluder implantation may be made more challenging by this anatomy because it is necessary to occlude the ostia of both lobes with the device. For better planning, we decided to simulate the actual procedure using three-dimensional (3D) printing technology. A computer-based hollow cast of the LAA was created from the 3D TEE data set and then converted to a stereolithography file for 3D printing using dedicated software (Mimics, Materialize Software, Leuven, Belgium; Figure [B]). An LAA model made of silicon was fabricated by 3D printing (Figure [C]). When a 24-mm Watchman device (d) was deployed in the phantom LAA directing toward the anterior lobe (a; Figure [D]), a large peri-device gap remains (arrow; Figure [E]; Movie I in the Data Supplement). Limited by the depth of the LAA, a larger device was deemed impossible to fit in. We thus attempted to deploy the device from an alternative direction by placing the delivery sheath in the posterior lobe (p). As a result, both the anterior (red dotted line) and posterior (black dotted line) lobes were adequately covered (Figure [F]). En face view of the device (d) showed complete LAA seal (Figure [G]). Guided by these simulation results, a 24-mm WATCHMAN device (d) was deployed, completely sealing both the anterior (a) and the posterior lobes (p) without any peri-device leak (arrow; Figure [H]). Postimplantation 3D TEE showed complete LAA seal by the device (d; Figure [I]). Final device position was accurately predicted by phantom testing.

Catheter-based LAA occlusion has emerged as an alternative to oral anticoagulation for reducing atrial fibrillation-related stroke risk.¹ Currently, procedural planning for LAA occlusion was guided by TEE and fluoroscopy and procedural

success rate is high. However, marked age- and sex-related differences in LAA anatomy exist. The existence of multi-lobed appendages is important in the accurate TEE evaluation of LAA. Fifty-four percent of LAAs had 2 lobes.² Because lobes exist in different planes, imaging must be done in multiple planes to visualize the entire LAA. Complexity and variability of LAA morphology sometimes pose challenges to device implantation, potentially leading to repeated deployment attempts, incomplete seal, procedural complications, and failure.³ The process of 3D printing refers to the conversion of 3D computerized models into physical replica.⁴ It is now feasible to 3D print patient-specific LAA models from 3D data sets acquired by 3D imaging techniques using materials that mechanically mimic atrial soft tissues. This report illustrates the techniques and advantages of 3D printing in facilitating LAA occlusion in cases with challenging LAA anatomy by enhancing appreciation of LAA morphology and enabling simulation of device deployment before the actual procedure.

Sources of Funding

This work is partially supported by General Research Fund of the Research Grant Committee (467812) and internal funding of the Department of Medicine and Therapeutics, The Chinese University of Hong Kong.

Disclosures

Dr Lee received research equipment support and speaker honorarium from Philips Healthcare. Mr Zhang was an employee of Boston Scientific Inc. The other authors report no conflicts.

References

1. Holmes DR, Reddy VY, Turi ZG, Doshi SK, Sievert H, Buchbinder M, Mullin CM, Sick P; PROTECT AF Investigators. Percutaneous closure of the left atrial appendage versus warfarin therapy for prevention of stroke in patients with atrial fibrillation: a randomised non-inferiority trial. *Lancet*. 2009;374:534–542. doi: 10.1016/S0140-6736(09)61343-X.
2. Veinot JP, Harrity PJ, Gentile F, Khandheria BK, Bailey KR, Eickholt JT, Seward JB, Tajik AJ, Edwards WD. Anatomy of the normal left atrial appendage: a quantitative study of age-related changes in 500 autopsies

Received January 3, 2016; accepted February 8, 2016.

From the Division of Cardiology, Department of Medicine and Therapeutics, Prince of Wales Hospital, Faculty of Medicine, The Chinese University of Hong Kong, Hong Kong, China (Y.F., G.S.-H.C., A.K.-Y.C., A.P.-W.L.); Department of Mechanical Engineering, The University of Hong Kong, Hong Kong, China (K.-W.K.); Cardiology Department, Renji Hospital, Medical College of Shanghai Jiao Tong University, Shanghai, China (Y.F.); and Boston Scientific Institute for Advancing Science, Shanghai, China (Y.Z.).

The Data Supplement is available at <http://circinterventions.ahajournals.org/lookup/suppl/doi:10.1161/CIRCINTERVENTIONS.116.003561/-DC1>.

Correspondence to Alex Pui-Wai Lee, MD, 9/F Department of Medicine and Therapeutics, Lui Che Woo Clinical Sciences Bldg, Prince of Wales Hospital, 30–32 Ngan Shing St, Shatin, N.T., Hong Kong SAR, China. E-mail alexpwlee@cuhk.edu.hk

(*Circ Cardiovasc Interv*. 2016;9:e003561. DOI: 10.1161/CIRCINTERVENTIONS.116.003561.)

© 2016 American Heart Association, Inc.

Circ Cardiovasc Interv is available at <http://circinterventions.ahajournals.org>

DOI: 10.1161/CIRCINTERVENTIONS.116.003561

hearts: implications for echocardiographic examination. *Circulation*. 1997;96:3112–3115.

- Viles-Gonzalez JF, Kar S, Douglas P, Dukkipati S, Feldman T, Horton R, Holmes D, Reddy VY. The clinical impact of incomplete left atrial appendage closure with the Watchman Device in patients with atrial fibrillation: a PROTECT AF (Percutaneous closure of the left atrial appendage versus warfarin therapy for prevention of stroke in patients with

atrial fibrillation) substudy. *J Am Coll Cardiol*. 2012;59:923–929. doi: 10.1016/j.jacc.2011.11.028.

- Kim MS, Hansgen AR, Wink O, Quaife RA, Carroll JD. Rapid prototyping: a new tool in understanding and treating structural heart disease. *Circulation*. 2008;117:2388–2394. doi: 10.1161/CIRCULATIONAHA.107.740977.

KEY WORDS: atrial appendage ■ atrial fibrillation ■ printing

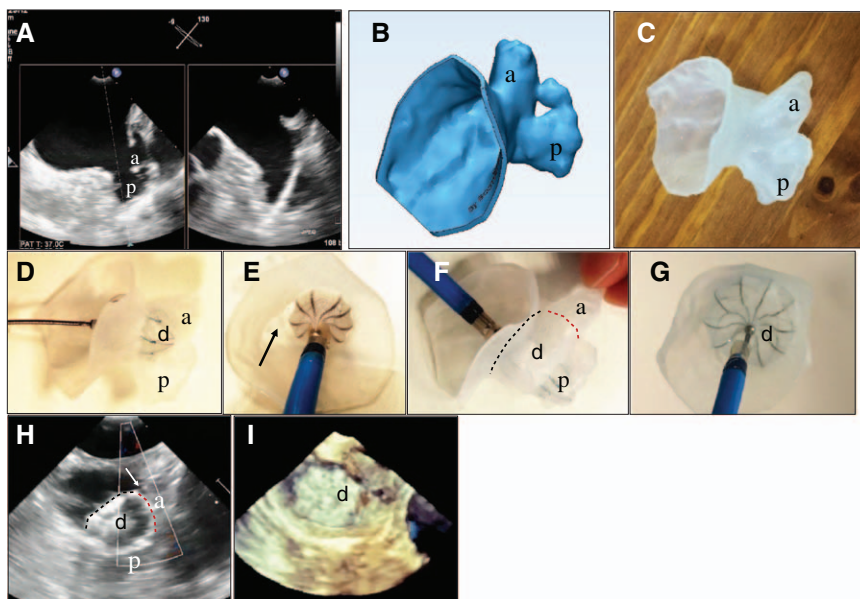


Figure. Three-dimensional printing of a double-lobed left atrial appendage for simulation of the occlusion procedure using a Watchman device. **A**, Preprocedural transesophageal echocardiography (TEE) using the biplane mode. **B**, Computer-based hollow cast. **C**, Model made of silicon was fabricated by 3D printing. **D**, Watchman device deployed in simulation. **E**, Peri-device gap. **F**, Simulation showed coverage of both anterior and posterior lobes. **G**, En face view. **H**, Watchman device deployed. **I**, Postimplantation 3D TEE showed complete seal. a indicates anterior lobe; d, Watchman device; and p, posterior lobe.